Acta Biologica Turcica, 39(2), kswg20260204-11p Received 02 Sep. 2026; Accepted 19 Oct. 2026; Published Online 25 Nov. 2026

ACTA BIOLOGICA TURCICA

© 1950-1978 Biologi, Türk Biologi Dergisi, Türk Biyoloji Dergisi, Acta Biologica

E-ISSN: 2458-7893, http://www.actabiologicaturcica.com

Case Report

Gross necropsy findings in a stranded Mediterranean monk seal (Monachus monachus) and implications for conservation in Türkiye

Ertan TAŞKAVAK[1,*], Sinan OKÇUOĞLU[2], Hande ÖZYOĞURTÇU[3]

[1]Ege University, Faculty of Fisheries, Bornova, İzmir, Türkiye
[2]İzmir Metropolitan Municipality, Directorate of Marine Protection, İzmir, Türkiye
[3]İzmir Metropolitan Municipality, Directorate of Natural Life Park, İzmir, Türkiye
*Corresponding author: ertantaskavak@yahoo.com

Abstract: This study reports necropsy findings from an adult female Mediterranean monk seal (*Monachus monachus*) stranded on 4 October 2023 in Foça, Türkiye, and considers their conservation implications. Subcutaneous fat thickness was measured as 7.00 cm at the median line of the thorax, indicating substantial adipose reserves. Because no validated body-condition index or species-specific reference interval exists for *M. monachus*, this value is reported descriptively and is not used to assign a categorical nutritional status; a single fat-depth measurement at one anatomical site should not be equated automatically with overall health. The seal exhibited no external trauma, entanglement, or other anthropogenic injuries. A pre-existing right ocular abnormality consistent with anophthalmia, of undetermined origin, was documented; this feature had reportedly enabled long-term photo-identification. Gross examination identified lesions compatible with extensive pulmonary disease, airway material of mucoid appearance, a pale rounded cardiac silhouette, post-mortem blood clot separation, and intestinal changes suggestive of enteritis with yellow fluid. The stomach was empty, indicating absence of recent feeding but not, by itself, establishing preterminal anorexia. No grossly visible parasites or ascites were observed, and no macroscopic evidence of pregnancy was detected. Overall, the gross findings were compatible with severe respiratory and gastrointestinal disease; however, a definitive cause and etiology of death could not be established without histopathological and microbiological confirmation, and the terms used here describe gross observations rather than confirmed diagnoses. Although the species was recently downlisted by IUCN from Critically Endangered to Vulnerable, this case highlights the importance of disease surveillance, even within a Special Environment Protection Area and in individuals with substantial subcutaneous fat reserves. The study underscores that a single fat-depth measurement does not preclude fatal pathology and highlights the limitations of using body condition as a sole health indicator. Conservation strategies should therefore include pathogen screening, standardized necropsy protocols with histopathology and microbiology, strengthened stranding response networks, and continued photo-identification monitoring. These measures are essential to provide evidence-based management guidance and ensure the long-term survival of *M. monachus* in Türkiye and across its fragmented range.

Keywords: Pinniped mortality, pneumonia, stranding response, marine conservation, Foça, disease surveillance

Citing: Taşkavak, E., Okçuoğlu, S., & Özyoğurtçu, H. (2026). Gross necropsy findings in a stranded Mediterranean monk seal (*Monachus monachus*) and implications for conservation in Türkiye. *Acta Biologica Turcica,* 39(2), kswg20260204-11p.

Introduction

The Mediterranean monk seal (*Monachus monachus*), one of the world's rarest pinnipeds, has experienced a severe decline in both population size and geographic distribution over the past century. Once abundant across the Mediterranean basin and eastern Atlantic coasts, the species is now restricted to fragmented populations in Greece, Türkiye, Cyprus, Mauritania, and Madeira. The most recent global estimate is 815–997 total individuals, including approximately 440–540 mature individuals (Marine Mammal Commission, 2015). The International Union for Conservation of Nature (IUCN) listed the species as "Critically Endangered" from 1996 until 2015, when it was reassessed as "Endangered" at the species level (Karamanlidis & Dendrinos, 2015; IUCN, 2019). In 2023, the species was downlisted to "Vulnerable" (VU) under Criterion D1, with an estimated 450–600 mature individuals, reflecting successful long-term conservation efforts (Karamanlidis et al., 2023; Endangered Landscapes & Seascapes Programme, 2026). The Eastern Mediterranean subpopulation, however, remains classified as "Endangered" (EN D) (IUCN, 2019). Türkiye plays a critical role in conserving *M. monachus*. Based on expert judgment and annual pup counts, the number of Mediterranean monk seals in Türkiye has been estimated at 76–140 total individuals, including 42–120 mature individuals (Karamanlidis et al., 2023; Karamanlidis, 2024). Historical records show that monk seals were once widespread along the Turkish Black Sea, Marmara, and Aegean coasts (Kıraç & Savaş, 1996). However, deliberate killings, overfishing, and habitat degradation have caused local extinctions—particularly in the Black Sea, where no confirmed sightings have been reported since 1997 (Güçlüsoy & Savaş, 2003; Kıraç et al., 2013). Today, breeding and regular sightings are confined to strongholds such as Foça, Datça Peninsula, Karaburun, and the Cilician Basin (Güçlüsoy & Savaş, 2003; Kıraç et al., 2013).

Despite the designation of Special Environment Protection Area (SEPA) and national action plans, monk seals in Türkiye continue to face severe human-caused pressures. Coastal urbanization, illegal fishing, disturbance of breeding caves, and marine pollution remain persistent threats (Güçlüsoy et al., 2004; Taşkavak and Özel, 2021). As upper trophic-level marine mammals, monk seals are considered sentinels of ecosystem health; their pathology can reflect broader ecological imbalances, including prey availability, habitat degradation, and bioaccumulation of pollutants (Lennon et al., 2025). Competition with artisanal fisheries has occasionally resulted in deliberate killings, highlighting the social and economic dimensions of conservation challenges (Güçlüsoy and Savaş, 2003; Taşkavak and Özel, 2021).

Foça, located at the northeastern entrance of İzmir Bay, is one of the most important habitats for the species. Declared a Special Environment Protection Area in 1990, Foça hosts pristine coasts, rich biodiversity, and critical breeding sites for monk seals (Kıraç and Güçlüsoy, 2008). Conservation efforts led by SAD-AFAG since the late 1980s have combined field monitoring, habitat protection, and community engagement, positioning the monk seal as both a flagship and umbrella species for broader marine ecosystem conservation. Recent monitoring efforts, supported by UNEP/MAP and national institutions, confirm that the species maintains resident individuals and breeding groups along Turkish coasts (Kıraç et al., 2013; Dendrinos et al., 2022). These findings underscore Türkiye's global responsibility—safeguarding *Monachus monachus* is essential not only for the survival of one of the world's rarest marine mammals but also for maintaining the ecological integrity of the eastern Mediterranean.

Necropsy of stranded marine mammals provides essential data on causes of death, disease presence, and anthropogenic interactions that cannot be obtained from external examination alone (Lennon et al., 2025). For endangered species such as the Mediterranean monk seal, such data are particularly valuable, yet well-documented necropsy reports from Türkiye remain scarce. Most available records are limited to stranding inventories and external examinations (Danyer et al., 2013, 2014, 2018), and few provide systematic gross pathological descriptions with morphometric and organ-level findings. This gap limits the ability to distinguish natural disease from anthropogenic mortality and to establish baseline health parameters for the species in Turkish waters. The present case is informative for several reasons. First, the carcass was fresh and showed no signs of decomposition, allowing a complete gross necropsy before post-mortem changes could compromise pathological assessment. Second, the individual was a known adult female ("Duygu") with a long-term photo-identification history, including a congenital right-sided ocular abnormality, which enabled precise individual recognition and linkage to monitoring records. Third, the stranding occurred within the Foça Special

Environment Protection Area, one of the species' key strongholds in the eastern Mediterranean, where anthropogenic pressures and conservation measures coexist. Fourth, the animal was in good nutritional condition (7.00 cm subcutaneous fat) despite extensive pulmonary and intestinal lesions, offering a clear example that body condition alone is an insufficient health indicator. By reporting these findings, this study aims to contribute baseline pathological and morphometric data, highlight the role of necropsy in monk seal health surveillance, and support evidence-based conservation for this Vulnerable species.

Material and Methods

On 04 October 2023 at 14:30, a deceased adult female Mediterranean monk seal (*Monachus monachus* Hermann, 1779) was recovered from the shoreline at Acar Camping, Foça, Türkiye (coordinates: 38.73196081955444°N, 26.74289776522207°E). A concerned citizen reported the animal to the General Directorate of Nature Conservation and National Parks (DKMP), Ministry of Agriculture and Forestry, stating that the seal appeared alive. Upon arrival of the research team, a representative of the Underwater Research Society - Mediterranean Seal Research Group (SAD-AFAG) confirmed that the individual (code name “Duygu”) was part of their active monitoring program. The rapid response aligns with best practices for stranding networks, which are essential for maximizing data recovery from carcasses before decomposition compromises pathological assessment (Lennon et al., 2025). The carcass was transported to İzmir Metropolitan Municipality Natural Life Park, where a comprehensive necropsy began at 18:30 on the same day. The specimen showed no signs of decomposition at the time of examination, which is critical because advanced decomposition and scavenger damage significantly increase the odds of incomplete necropsy reports (Lennon et al., 2025).

Necropsy was performed using a protocol adapted for pinnipeds, integrating the multi-tier framework and organ-system examination approach of the ACCOBAMS/ASCOBANS cetacean best-practice protocol (IJsseldijk et al., 2019) with pinniped-specific procedures from NOAA Fisheries' Pinniped Necropsy Guide and the quantitative pathology framework for marine mammals (Lennon et al., 2025). The IJsseldijk et al. (2019) protocol was originally developed for cetaceans and is explicitly intended as a harmonization framework transferable across marine mammal taxa; species-specific modifications for this monk seal included blubber thickness measurement at the median line and pinniped-appropriate flipper and skull morphometrics. Carcass decomposition condition was recorded as Code 1 (extremely fresh, no signs of decomposition) following the coding system in IJsseldijk et al. (2019). The carcass was positioned in dorsal recumbency. A mid-ventral incision was made from the mandible to the pubic symphysis, with lateral extensions to expose the thoracic and abdominal cavities. External examination preceded systematic internal organ evaluation. External features recorded included the presence of skin lesions, wounds, hematomas, and any congenital abnormalities. Nutritional status was assessed by measuring subcutaneous adipose tissue thickness at the median line of the thorax and pelvis using a standard ruler (precision ±1 mm). Body condition (BC) indices, such as fat thickness, are traditional proxies for health in marine mammals, although they offer a limited view of overall health and may not capture sub-lethal impacts or comorbidities (Lennon et al. 2025). Body mass was measured using a calibrated digital platform scale (accuracy ±0.5 kg; manufacturer not specified). Linear measurements were taken using a flexible metal tape measure (precision ±1 cm) and included: straight body length (nose to tail tip along the ventral midline), curved body length (dorsal contour following body curvature), nose-to-tail tip distance (straight line), chest circumference (at the level of the axillae), tail length, maximum right and left hind flipper lengths, and maximum skull circumference (at the widest frontal–parietal diameter). All measurements were recorded in centimeters (cm) except body mass in kilograms (kg). Pregnancy status was assessed by gross visual inspection of the uterus and ovaries; no other aspects of reproductive activity were evaluated.

The thoracic and abdominal cavities were opened systematically. The presence of ascites, hemothorax, or pericardial effusion was recorded. Organ examination included the heart, lungs, liver, spleen, kidneys, stomach, intestines, and reproductive tract. Each organ was assessed for color, size, consistency, and the presence of lesions, hemorrhage, or parasites. Organ dimensions were measured using a ruler (cm). Gross lesions were described macroscopically and recorded as observations rather than diagnoses; findings such as pulmonary lesions, intestinal changes, and cardiopulmonary alterations were

documented using terms such as "compatible with" or "suggestive of" the corresponding pathological processes. Pathological observations were recorded in prose but retrospectively interpreted using a categorical presence/absence framework, consistent with methods that transform qualitative observations into quantitative variables for analytical purposes (Lennon et al. 2025). The cardiovascular system was examined for coagulation status and serum appearance. No histopathological, microbiological, parasitological, or toxicological analyses were performed. This represents a major limitation: without histopathology and pathogen screening, the nature, chronicity, and etiology of the observed lesions could not be confirmed, and terms such as pneumonia, enteritis, infectious etiology, or sepsis are used here only to describe gross findings compatible with such processes, not as confirmed diagnoses (IJsseldijk et al., 2024; Lennon et al., 2025).

All findings were documented contemporaneously on a standardized necropsy data sheet. Photographs were taken using a mobile phone (model not specified) to record external and internal findings (Figs 1–7). No statistical treatment of data was applied, as this study reports descriptive findings from a single specimen, although supervised and unsupervised machine learning techniques have been used in larger datasets to identify pathological profiles and predict body condition from pathology variables (Lennon et al. 2025). The necropsy was conducted under the framework of the long-term Mediterranean monk seal monitoring program authorized by the DKMP, Ministry of Agriculture and Forestry, Türkiye. No live animals were used, and no experimental procedures were performed.

Results

The stranded specimen was an adult female Mediterranean monk seal (*Monachus monachus*) in good general nutritional condition. Subcutaneous fat thickness was measured at the median line of the thorax, following the pinniped-adapted protocol described above and consistent with standardized marine mammal necropsy procedures (IJsseldijk et al. 2019). The measurement was recorded as 7.00 cm at this single site. This measurement indicates substantial adipose reserves in this individual; however, a single fat-depth measurement at one anatomical site should not be equated automatically with overall health, and no published body-condition index specific to *M. monachus* was available for direct comparison (Lennon et al., 2025). External examination revealed an intact body with no limb deficiencies, no signs of trauma, and no abnormal skin conditions (Fig. 1). A right ocular abnormality consistent with anophthalmia was noted (Fig. 2A). The left eye was examined for comparison and appeared structurally normal, with an intact globe, cornea, and adnexa (Fig. 2B). The unilateral nature of the right-sided finding, together with its stable appearance over the individual's long-term photo-identification history, supports a congenital origin rather than an acquired or post-mortem change. This anomaly enabled individual recognition through long-term photo-identification monitoring, highlighting the value of congenital markers for population studies (Karamanlidis et al., 2023).



Figure 1. General condition of the Mediterranean monk seal after it was pulled ashore near Acar Camping, Eski Foça, İzmir.



Figure 2A. Right orbit of an adult female Mediterranean monk seal (*Monachus monachus*), carcass in dorsal recumbency. The globe is absent, and the orbit is occupied by a smooth, closed conjunctival surface without visible cornea, sclera, or ocular adnexa, consistent with congenital anophthalmia. Periocular skin and eyelids are intact, with no evidence of trauma. The gloved finger provides an approximate size reference.



Figure 2B. Left (contralateral) eye of an adult female Mediterranean monk seal (*Monachus monachus*). The globe is present and normally positioned; the nictitating membrane is partially extended, and the conjunctiva, cornea, and sclera appear intact. This normal contralateral eye supports a congenital, unilateral origin for the right-sided anomaly. The gloved fingers provide an approximate size reference.

Observations recorded at the time of recovery, before transport to the necropsy facility, were distinguished from those made during necropsy (IJsseldijk et al., 2019). At recovery, a serous, trunk-red discharge with a slight mucoid structure was observed at the nose, and yellow fluid was reported from the mouth and the anus, with minimal yellow contamination noted at the anal opening. The oral fluid was of indeterminate origin; because the mouth could not be opened and no further examination was possible, it was not possible to distinguish gastric reflux from airway discharge, and this finding is therefore reported as indeterminate. During necropsy, the gingiva showed color variation from yellow to purple, and the conjunctivas were yellowish-brown (Fig. 3). These color changes are compatible with icterus or hepatic involvement, though no liver pathology was observed macroscopically. The mucosal discoloration was recorded descriptively; its cause could not be determined grossly, particularly in the absence of corroborating liver lesions or laboratory data (Lennon et al. 2025). The mouth could not be opened during necropsy owing to post-mortem jaw rigidity, which is reported here descriptively; trismus, which implies a clinical or pathological process, cannot be inferred from gross examination alone (IJsseldijk et al., 2024). The teeth were yellow with wear on the canines.

The individual weighed 214 kg, with a straight body length of 245 cm, curved body length of 255 cm, and nose-to-tail tip distance of 228 cm. Chest circumference measured 148 cm, tail length was 15 cm, maximum right hind flipper length was 44.5 cm, maximum left hind flipper length was 44 cm, and maximum skull circumference was 68 cm. These measurements provide baseline morphometric data for the individual. Subcutaneous connective and adipose tissues showed no vascularity and appeared slightly anemic. The fat tissue layer thickness at the median line was 7.00 cm. All muscles were dark red, nearly black. This discoloration may be compatible with myoglobinuria or post-mortem change, but without histology, a definitive diagnosis is not possible. The significance of this dark muscle coloration could not be determined from gross examination alone.



Figure 3. Nasal discharge in an adult female Mediterranean monk seal (*Monachus monachus*). A yellow-orange, mucoid discharge is present at the external nares, with no blood, purulent material, or foamy exudate visible. The discharge is described descriptively; no grading scale was applied. The gloved hand provides an approximate size reference.

No ascites or blood accumulation was observed in the abdomen. The carcass remained well preserved at the time of necropsy. The liver was normal in color and appearance, with no pathological lesions on section. The spleen measured 50.00 cm in length, with a uniform pattern across the entire surface and no evidence of hyperplasia **(**Fig. 4). No reference interval was available in this study to classify spleen length as normal or abnormal. The intestines were pale with loss of normal folds. The stomach was empty; gastric folds were smooth with no lesions, though a yellow-orange, slightly mucoid fluid was present on the stomach wall. No gastric hemorrhage or parasites were observed. The empty stomach indicates a lack of recent feeding, which is an important clinical sign compatible with pre-terminal anorexia. These gross intestinal changes were suggestive of enteritis, but histopathological confirmation was not available. The kidneys measured 29.00 cm in length, with characteristic structure and no abnormal findings on section **(**Fig. 5). Gross visual inspection of the uterus and ovaries revealed no macroscopic evidence of pregnancy. No assessment of other aspects of reproductive activity (e.g., cyclicity, recent ovulation, or previous pregnancy history) was possible based on gross examination alone.



Figure 4. Spleen (lien) of an adult female Mediterranean monk seal (*Monachus monachus*) showing a homogeneous external appearance without gross evidence of hemorrhage, hyperplasia, or focal lesions.



Figure 5. Kidneys (renes) of an adult female Mediterranean monk seal (*Monachus monachus*), showing normal gross morphology and characteristic internal architecture, with no apparent pathological alterations on section.

In the thorax, no fluid was present. Solidified serum with a "chicken fat" appearance was observed in the

cardiovascular system (Fig. 6). This finding may be compatible with acute cardiovascular insufficiency and poor post-mortem clotting, often associated with septic or infectious processes; however, post-mortem separation of blood components can produce a "chicken fat" appearance, and this finding is nonspecific and should not be considered diagnostic of cardiovascular insufficiency or sepsis. The heart was pale and slightly spherical in structure, with no coagulation observed in the atria or ventricles (Fig. 6). Gross pulmonary lesions compatible with generalized pneumonia were present, and mucoid aspirates were observed in sections (Fig. 7).



Figure 6. Heart and great vessels of an adult female Mediterranean monk seal (*Monachus monachus*). The heart appears pale and slightly spherical. No coagulated blood is present within the atria or ventricles. Solidified serum with a "chicken fat" appearance is visible in the cardiovascular system; this appearance is consistent with post-mortem separation of blood components and represents a nonspecific finding without diagnostic significance for the cause of death.

The condition of the stomach and intestines indicated that food had not been consumed for some time. Despite the absence of recent food intake, the good body condition (7.00 cm subcutaneous fat) ruled out starvation as the cause of death. The substantial subcutaneous fat reserve made severe chronic emaciation unlikely but did not, by itself, exclude reduced recent intake or other nutritional effects, consistent with the observation that changes in body condition often become apparent only after health has become severely compromised (Lennon et al. 2025). Findings in the heart and lungs were compatible with severe pneumonia and suggested cardiopulmonary compromise (Fig. 6 & Fig. 7). The animal appeared to have remained in a prolonged state of agony. The duration and severity of pre-mortem distress could not be determined from the gross examination. Consequently, the macroscopic findings raise the possibility that death was associated with cardiopulmonary compromise secondary to severe pulmonary and intestinal lesions; however, this cannot be confirmed without ancillary diagnostics.

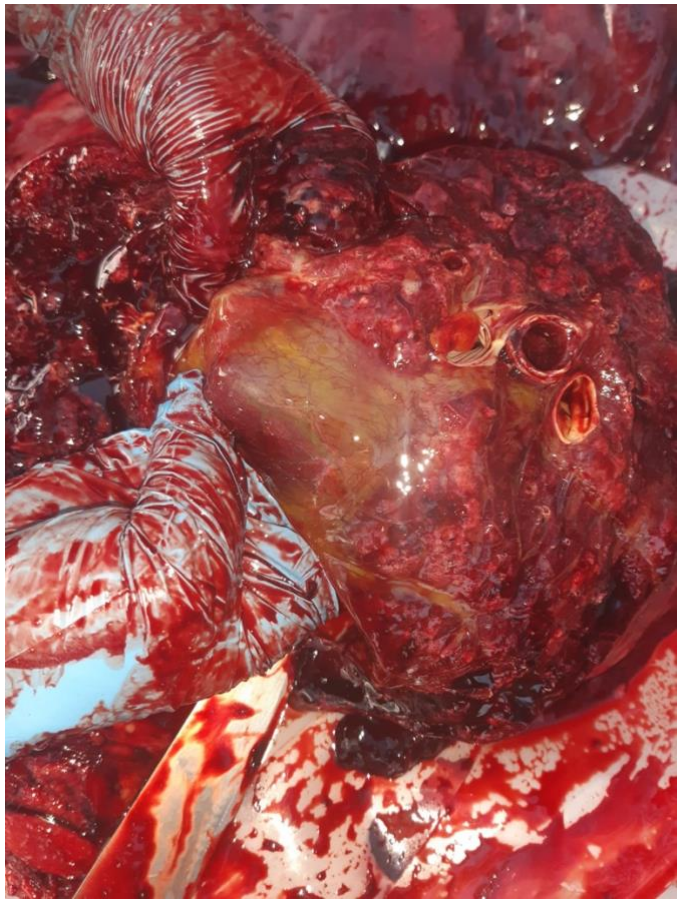

Figure 7. Lungs of an adult female Mediterranean monk seal (*Monachus monachus*) examined in situ following reflection of the thoracic wall and after removal from the thoracic cavity. The lungs exhibited diffuse, dark-red pulmonary consolidation characterized by a firm consistency and marked loss of the normal spongy parenchymal architecture. Mucoid exudate was observed within the bronchi and on the pleural surface. No evidence of pleural effusion, hemothorax, or pericardial effusion was detected. Gross pathological findings were consistent with severe pneumonia and suggested an infectious respiratory process; however, the underlying etiology could not be determined because microbiological and histopathological examinations were not performed.

Discussion

The necropsy findings suggest that natural disease processes may have contributed substantially to mortality in this Mediterranean monk seal, even within

a protected area and in an individual in good nutritional condition. This aligns with observations in other marine mammals, where respiratory and hepatic pathologies emerge as key indicators of health status, regardless of body condition (Lennon et al. 2025). The absence of trauma, fisheries interaction, or anthropogenic injury distinguishes this case from previously documented strandings along the Turkish Aegean and Mediterranean coasts, where deliberate killing accounted for 2 of 18 cases (11.1%) between February 2012 and April 2018 (Danyer et al., 2013, 2014, 2018). However, most strandings in that seven-year period had undetermined or natural causes, reinforcing that non-anthropogenic mortality is not rare (Danyer et al., 2018)

The gross pulmonary lesions and mucoid airway material were compatible with severe respiratory disease. However, an infectious etiology and cardiopulmonary failure cannot be established without histopathology and pathogen testing. The “chicken fat” appearance of post-mortem blood is nonspecific and, as noted earlier, was not interpreted as evidence of cardiovascular insufficiency or sepsis. In Mediterranean monk seals specifically, morbillivirus infections have been documented in stranded individuals from Greece and in carcasses from a mass mortality event in Mauritania (van de Bildt et al., 1999; Osterhaus et al., 1997), and co-infection with cetacean morbillivirus and *Toxoplasma gondii* has been reported in a monk seal pup, producing diffuse interstitial pneumonia with bronchiolar epithelial hyperplasia (Mazzariol et al., 2021). Additionally, a monk seal from the Turkish Aegean coast was found infected with *Acanthocheilonema spirocauda* in the right cardiac ventricle (Papadopoulos et al., 2010), a filarioid nematode known to cause cardiovascular and pulmonary arterial lesions and pneumonia in pinnipeds under heavy infection loads. In other pinniped and cetacean species, respiratory disease is a well-established major cause of mortality (Bogomolni et al., 2015), and in harbour porpoises, respiratory pathology and parasites explain a substantial proportion of variation in pathological data (Lennon et al., 2025). These findings from other taxa support the plausibility of an infectious respiratory process in the present case, but they are extrapolated from species other than *Monachus monachus* and cannot be used to infer a specific etiology here. In monk seals from Turkish waters specifically, a 2013 stranding of an emaciated adult female with gastrointestinal nematode, cestode, and trematode infestation showed gross evidence of verminous intoxication or systemic infection leading to internal bleeding and hypovolemic shock (Danyer et al., 2013). In the present case, the concurrent thickening of the intestinal wall and yellow fluid were gross changes suggestive of enteritis, but their etiology and relationship to the pulmonary lesions remain undetermined without histopathology and parasitological examination.

Contrary to previous necropsy reports from the region, which documented severe parasitic infestations leading to chronic debilitation (Castinel et al., 2006; Nadler et al., 2013; Ramos et al., 2013), the present specimen exhibited no grossly visible parasites and maintained good body condition, with a subcutaneous fat thickness of 7.00 cm. Lennon et al. (2025) identified age class and parasitism across multiple organ systems as the strongest predictors of body condition index, given that high parasite burdens negatively affect energy balance. Nevertheless, the absence of grossly visible parasites does not preclude subclinical or microscopic parasitism, nor does it confirm an acute disease process. However, the absence of recent food intake may indicate a brief period of physiological distress preceding death. Collectively, these observations support previous reports indicating that blubber thickness in the Mediterranean monk seal is a reliable indicator of body condition and overall health status. The earliest available record, from Çeşme prior to 2001, described an individual with an extremely reduced subcutaneous fat layer (0.5 cm), associated with severe malnutrition, osteoporosis, and prolonged starvation (Schütte, 2001). Conversely, a subadult male necropsied on 1 May 2009 exhibited substantial thoracic (35 mm) and abdominal (40 mm) blubber reserves and was considered to be in good nutritional condition; its death resulted from acute drowning rather than a health-related impairment (Karamanlidis et al., 2011). On 25 March 2012, a young female from Libya presented thoracic and abdominal blubber thicknesses of 25 mm and 30 mm, indicative of good nutritional and health status (Alfaghi et al., 2013). On 26 March 2017, a 5-month-old pup from Foça had an abdominal blubber thickness of approximately 50 mm, with no evidence of disease (Kıraç & Ok, 2019). In contrast, among the cases reported by Danyer et al. (2018), an immature individual found in Antalya on 25 November 2017 had a blubber thickness of 1.3 cm and a heavy nematode infestation; an adult female found in Muğla/Datça on 7 March 2018 had a blubber

thickness of 2.8 cm, with gingivitis, gastric ulcers, and cestodes; and another adult female found in İzmir/Seferihisar on 16 April 2018 had a blubber thickness of only 0.5 cm, was cachectic, and exhibited multiple parasitic infestations. These chronological data suggest that high blubber thickness is associated with adequate nutrition, whereas markedly reduced blubber thickness is linked to chronic starvation, disease, and immune deficiency. However, as observed in the adult female with a blubber thickness of 2.8 cm, severe pathologies may occur even when blubber thickness appears within the normal range; therefore, blubber measurements alone are insufficient and should be complemented by full necropsy and laboratory analyses (Danyer et al., 2018; Schütte, 2001). Collectively, these observations underscore that while blubber thickness serves as a valuable rapid indicator of nutritional reserves, it must be interpreted alongside comprehensive pathological and parasitological findings to accurately assess the health status of Mediterranean monk seals.

Human and natural factors often interact at the population level. Chronic disturbance from coastal urbanization and boat traffic has been suggested to weaken immune defenses, and pollution may increase susceptibility to infections in Mediterranean monk seals (Dendrinos et al. 2008). As Lennon et al. (2025) note, adults in good nutritional condition can still have underlying moderate pathologies that suggest compromised health, indicating low capacity to deal with additional stressors. Although no direct anthropogenic injury was found, the observed pulmonary and intestinal lesions could be indirect consequences of environmental stressors that compromise seal health; however, this individual case provides no direct evidence linking the observed lesions to environmental stressors. In the present case, no contaminant, stress, immune, or exposure data were collected. The coexistence of a natural disease process as the immediate finding and human activities as potential population-level contributors underscores the need for integrated conservation strategies (Karamanlidis et al. 2015), but it does not establish a causal role for anthropogenic stressors in this specific mortality.

The Mediterranean monk seal's IUCN status improved from Critically Endangered to Vulnerable in 2023, reflecting successful long-term conservation programs (Karamanlidis et al., 2023).However, the present case demonstrates the value of disease surveillance even in well-protected habitats.As highlighted by Lennon et al. (2025), assessing long-term population health is an important aspect of wildlife monitoring, and necropsies provide a critical appraisal of pathology that gives insights into proximate causes of death and organ functionality. Therefore, sustained recovery requires more than habitat protection and anti-poaching measures. Systematic pathogen screening, standardized necropsy protocols following quantitative frameworks (IJsseldijk et al., 2024; Lennon et al., 2025), and integrated disease surveillance should become routine components of monk seal conservation. The rapid response enabled by the SAD-AFAG monitoring program and community reporting proved critical in this case, highlighting the value of stranding networks. Moreover, incomplete necropsy reports—often caused by scavenger damage or freezing—represent a huge loss of information, and future efforts should explore data imputation methods to maximize the use of stranding data (Lennon et al., 2025).

This study is limited by the absence of histopathology, microbiology, and toxicology. No tissues were collected or archived from this animal; consequently, no archived material exists, and histopathological, microbiological/PCR, or toxicological analyses cannot be performed retrospectively. Without histology, it is impossible to confirm the nature and chronicity of the pulmonary lesions or to determine an etiology (e.g., viral, bacterial, fungal, or non-infectious). Likewise, no parasitological examination was performed, so subclinical parasitism cannot be ruled out. Future studies should adopt the multi-organ, multi-disciplinary approach recommended by Lennon et al. (2025), including gross pathology, histology, and molecular diagnostics, and should ensure that tissues are systematically archived at the time of necropsy so that ancillary analyses remain possible.

In conclusion, gross necropsy findings in this adult female identified severe pulmonary and intestinal abnormalities that may have contributed to death, but the definitive cause and etiology remain unresolved in the absence of ancillary diagnostics. This case reinforces that body condition alone is insufficient as a health indicator, as individuals with good nutritional status can have fatal underlying pathology (Lennon et al. 2025). Conservation efforts must therefore balance addressing direct human impacts with strengthening veterinary and epidemiological capacity.

Strengthened stranding response networks, routine necropsy with histopathology and microbiology, and continued long-term photo-identification—as exemplified by the right-sided anophthalmia that enabled individual recognition—are essential for generating the evidence needed to guide management and secure the future of *Monachus monachus* in Türkiye and across its range.

Acknowledgements
We thank the DKMP officials who reported the case and assisted with transporting the seal carcass, as well as the SAD-AFAG representative who met us at the scene and provided clarification upon our arrival. We are deeply grateful to the anonymous reviewers for their valuable feedback and thoughtful recommendations, which significantly enhanced the quality, clarity, and overall impact of the manuscript during the initial stages of its development.

Ethical Approval
No need to ethical approval for this study.

Conflicts of Interest
The authors declare no conflict of interest.

Funding Statement
The study was not supported by any institution.

References
Alfaghi, I. A., Abed, A. S., Dendrinos, P., Psaradellis, M., & Karamanlidis, A. A. (2013). First confirmed sighting of the Mediterranean monk seal (*Monachus monachus*) in Libya since 1972. *Aquatic Mammals, 39*(1), 81–84. https://doi.org/10.1578/AM.39.1.2013.81

Bogomolni, A., Frasca, S., Levin, M., Matassa, K., Nielsen, O., Waring, G., & de Guise, S. (2015). In vitro exposure of harbor seal immune cells to Aroclor 1260 alters phocine distemper virus replication. *Archives of Environmental Contamination and Toxicology, 69*, 408–418. https://doi.org/10.1007/s00244-015-0178-z

Castinel, A., Duignan, P. J., Pomroy, W. E., Lyons, E. T., Nadler, S. A., Dailey, M. D., Wilkinson, I. S., & Chilvers, B. L. (2006). First report and characterization of adult *Uncinaria* spp. in New Zealand sea lion (*Phocarctos hookeri*) pups from the Auckland Islands, New Zealand. *Parasitology Research, 98*(4), 304–309. https://doi.org/10.1007/s00436-005-0069-8

Danyer, E., Özbek, E. Ö., Aytemiz, I., & Tonay, A. M. (2013). Preliminary report of a stranding case of Mediterranean monk seal *Monachus monachus* (Hermann, 1779) on Antalya coast, Turkey, April 2013. *Journal of the Black Sea/Mediterranean Environment, 19*(2), 278–282.

Danyer, E., Aytemiz, I., Gücü, A. C., & Tonay, A. M. (2014). Preliminary study on a stranding case of Mediterranean monk seal *Monachus monachus* (Hermann, 1779) on the Eastern Mediterranean coast of Turkey. *Journal of the Black Sea/Mediterranean Environment, 20*(2), 152–157.

Danyer, E., Aytemiz Danyer, I., Tonay, A. M., Erol, U., & Dede, A. (2018). Stranding records of Mediterranean monk seal *Monachus monachus* (Hermann, 1779) on the Aegean and Mediterranean Sea coasts of Turkey between 2012 and 2018. *Journal of the Black Sea/Mediterranean Environment, 24*(2), 128–139.

Dendrinos, P., Karamanlidis, A. A., Kotomatas, S., Paravas, V., & Adamantopoulou, S. (2008). Report of a new Mediterranean monk seal (*Monachus monachus*) breeding colony in the Aegean Sea, Greece. *Aquatic Mammals, 34*(3), 355–361. https://doi.org/10.1578/AM.34.3.2008.355

Dendrinos, P., Adamantopoulou, S., Koemtzopoulos, K., Mpatzios, P., Paxinos, O., Tounta, E., Tsiakalos, D., & Karamanlidis, A. A. (2022). Anecdotal observations of open beach use by female Mediterranean monk seals (*Monachus monachus*) and their pups in Greece: Implications for conservation. *Aquatic Mammals, 48*(6), 602–609. https://doi.org/10.1578/AM.48.6.2022.602

González, L. M. (2015). Prehistoric and historic distributions of the critically endangered Mediterranean monk seal (*Monachus monachus*) in the eastern Atlantic. *Marine Mammal Science, 31*(3), 1168–1192. https://doi.org/10.1111/mms.12228

Güçlüsoy, H., & Savaş, Y. (2003). Status of the Mediterranean monk seal, *Monachus monachus*, in the Foça Pilot Monk Seal Conservation Area, Turkey. *Zoology in the Middle East, 28*(1), 5–16. https://doi.org/10.1080/09397140.2003.10637951

Güçlüsoy, H., Kıraç, C. O., Veryeri, N. O., & Savaş, Y. (2004). Status of the Mediterranean monk seal, *Monachus monachus* (Hermann, 1779), in the coastal waters of Turkey. *Ege Journal of Fisheries and Aquatic Sciences, 21*(3–4), 201–210.

IJsseldijk, L. L., Brownlow, A. C., & Mazzariol, S. (2019). *European best practice on cetacean post-mortem investigation and tissue sampling*. ACCOBAMS/ASCOBANS. https://doi.org/10.31219/osf.io/zh4ra

IJsseldijk, L. L., van den Broek, J., Kik, M. J. L., Leopold, M. F., Bravo Rebolledo, E., Gröne, A., & Heesterbeek, H. (2024). Using marine mammal necropsy data in animal health surveillance: The case of the harbor porpoise in the Southern North Sea. *Frontiers in Marine Science, 10*, Article 1306294. https://doi.org/10.3389/fmars.2023.1306294

Karamanlidis, A. A., Kallianiotis, A., Psaradellis, M., & Adamantopoulou, S. (2011). Stomach contents of a subadult Mediterranean monk seal (*Monachus monachus*) from the Aegean Sea. *Aquatic Mammals,*

37(3), 280–283. https://doi.org/10.1578/AM.37.3.2011.280

Karamanlidis, A. A., Dendrinos, P., Fernández de Larrinoa, P., Gücü, A. C., Johnson, W. M., Kıraç, C. O., & Pires, R. (2016). The Mediterranean monk seal *Monachus monachus*: Status, biology, threats, and conservation priorities. *Mammal Review, 46*(2), 92–105. https://doi.org/10.1111/mam.12053

Karamanlidis, A. A., Dendrinos, P., Fernández de Larrinoa, P., Kıraç, C. O., Nicolaou, H., & Pires, R. (2023). *Monachus monachus*. *The IUCN Red List of Threatened Species 2023*, e.T13653A238637039. https://doi.org/10.2305/IUCN.UK.2023-1.RLTS.T13653A238637039.en

Karamanlidis, A. A. (2024). Current status, biology, threats and conservation priorities of the Vulnerable Mediterranean monk seal. *Endangered Species Research, 53*, 341–361. https://doi.org/10.3354/esr01304

Kıraç, C. O., & Savaş, Y. (1996). Status of the monk seal (*Monachus monachus*) in the neighbourhood of Ereğli, Black Sea coast of Turkey. *Zoology in the Middle East, 12*, 5–12.

Kıraç, C. O., & Güçlüsoy, H. (2008). *Foça and Mediterranean monk seal: Conservation and monitoring of the Mediterranean monk seals (Monachus monachus) in Foça Special Environment Protection Area*. Environment Protection Agency for Special Areas.

Kıraç, C. O., Veryeri, N. O., Güçlüsoy, H., & Savaş, Y. (2013). *National action plan for the conservation of Mediterranean monk seal Monachus monachus in Türkiye*. UNEP/MAP–RAC/SPA and Republic of Türkiye Ministry of Forest and Water Works.

Kıraç, C. O., & Ok, M. (2019). Diet of a Mediterranean monk seal *Monachus monachus* in a transitional post-weaning phase and its implications for the conservation of the species. *Endangered Species Research, 39*, 315–320. https://doi.org/10.3354/esr00971

Lennon, R. L., Storm, J., Koger, R., Thompson, E., Williams, R. S., Dagleish, M. P., Babayan, S. A., ten Doeschate, M. T. I., Davison, N. J., & Brownlow, A. C. (2025). The dead do tell tales: Using pathology data from cetacean necropsy reports to gain insights into animal health. *Ecology and Evolution, 15*(9), Article e72119. https://doi.org/10.1002/ece3.72119

Mazzariol, S., Centelleghe, C., Petrella, A., Marcer, F., Beverelli, M., Di Francesco, C. E., Di Francesco, G., Di Renzo, L., Di Guardo, G., Audino, T., Tripodi, L., & Casalone, C. (2021). Atypical toxoplasmosis in a Mediterranean monk seal (*Monachus monachus*) pup. *Journal of Comparative Pathology, 184*, 65–71. https://doi.org/10.1016/j.jcpa.2021.02.005

Nadler, S. A., Lyons, E. T., Pagan, C., Hyman, D., Lewis, E. E., Beckmen, K., Bell, C. M., Castinel, A., DeLong, R. L., Duignan, P. J., Farinpour, C., Burek Huntington, K., Kuiken, T., Morgades, D., Naem, S., Norman, R., Parker, C., Ramos, P., Spraker, T. R., & Berón-Vera, B. (2013). Molecular systematics of pinniped hookworms (Nematoda: *Uncinaria*): Species delimitation, host associations and host-induced morphometric variation. *International Journal for Parasitology, 43*(14), 1119–1132. https://doi.org/10.1016/j.ijpara.2013.08.006

Osterhaus, A. D. M. E., Groen, J., Niesters, H. G. M., van de Bildt, M. W. G., Martina, B. E., Vedder, L., Vos, J. G., van Egmond, H., Ba, A. S., & Ould Barham, M. E. (1997). Morbillivirus in monk seal mass mortality. *Nature, 388*, 838–839. https://doi.org/10.1038/42163

Papadopoulos, E., Loukopoulos, P., Komnenou, A., Androukaki, E., & Karamanlidis, A. A. (2010). First report of *Acanthocheilonema spirocauda* in the Mediterranean monk seal (*Monachus monachus*). *Journal of Wildlife Diseases, 46*(2), 570–573. https://doi.org/10.7589/0090-3558-46.2.570

Ramos, P., Lynch, M., Hu, M., Arnould, J. P. Y., Norman, R., & Beveridge, I. (2013). Morphometric and molecular characterization of the species of *Uncinaria* Frölich, 1789 (Nematoda) parasitic in the Australian fur seal *Arctocephalus pusillus doriferus* (Schreber), with notes on hookworms in three other pinniped hosts. *Systematic Parasitology, 85*(1), 65–78. https://doi.org/10.1007/s11230-013-9407-x

Samaranch, R., & González, L. M. (2000). Changes in morphology with age in Mediterranean monk seals (*Monachus monachus*). *Marine Mammal Science, 16*(1), 141–157. https://doi.org/10.1111/j.1748-7692.2000.tb00909.x

Schütte, H.-J. (2001). *Osteoporosis in marine mammals* [Press release]. International Fund for Animal Welfare / Internationaler Tierschutz-Fonds / Gesellschaft zum Schutz der Meeressäugetiere.

Taşkavak, E., & Özel, F. V. (2021). Friendly aquaculture: Are fish farms unfairly held responsible for deaths of Mediterranean monk seal? In *Proceedings of HydroMediT 2021: 4th International Congress on Applied Ichthyology, Oceanography & Aquatic Environment* (pp. 336–340).

van de Bildt, M. W. G., Vedder, E. J., Martina, B. E., Sidi, B. A., Jiddou, A. B., Ould Barham, M. E., Androukaki, E., Komnenou, A., Niesters, H. G. M., & Osterhaus, A. D. M. E. (1999). Morbilliviruses in Mediterranean monk seals. *Veterinary Microbiology, 69*(1–2), 19–21.